

Cysticercosis in heart muscle of a heifer

S.M. Tamuli, A. Chakraborty and K.L. Jamir

Department of Pathology,
Assan Agricultural University, Khanapara,
Guwahati-781 022, India

Abstract

The occurrence of *Cysticercus bovis*, an intermediate stage of *Taenia saginata* along with sarcocystis in a heifer is reported. The gross and histopathological changes in the heart are described.

Keywords: Bovine, Cysticercosis, Histopathology, Heart.

Introduction

Incidence of cysticercosis in bovines is not uncommon and reported by Githigia *et al.* (1995) and Mori *et al.* (1996). The intermediate stage that mostly occurs in skeletal and cardiac muscle of cattle is termed as "measly beef." However, other organs, such as liver, lungs, tongue and diaphragm may also be affected. Mori *et al.* (1996) and Zinkovic *et al.* (1996) reported the location of intermediate stage in the heart muscle, however, record of its occurrence in the heart muscle of bovines in India is scanty (Ratnam and Khanna, 1988). The present communication documents the occurrence of *Cysticercus bovis* in the heart muscle of a cow.

Materials and Methods

A two years old heifer of the Department of Animal Physiology, College of Veterinary Science, Khanapara was received for post-mortem examination in the Department of Pathology. The animal was necropsied thoroughly and detailed investigation was carried out to ascertain the cause of death. The heart, liver, lung, kidney and intestine were collected and preserved in 10% formalin for histopathological examination. Paraffin embedded tissues were cut at 4-5 μ m thickness, stained with Haematoxylin and Eosin and examined as per standard procedure.

Results and Discussion

The carcass was submitted with the history that the animal was suffering from diarrhoea, dehydration, emaciation and anaemia. At necropsy, the liver showed greyish white necrotic foci at places while the small intestine showed haemorrhages. The most striking lesions found in the heart were numerous greyish white cysts which contain

a whitish granule in its fluid. The cysts were ranging in size from 5 to 9 mm, projecting from epicardium and endocardial surface, covering almost all parts of the heart muscle (Fig. 1). The cysts resemble *Cysticercus bovis* infection. McIntosh and Miller (1960) described similar type of cyst in the heart muscle of cattle with the developmental stages of *Taenia saginata*.

No significant changes could be recorded in different organs except the haemorrhagic enteritis. The lesions of the heart revealed areas of cystic cavities in the epicardium and endocardium and within it invaginated scolices were present which were devoid of hooks and thus were identified as the bladder worm of *Cysticercus bovis* (Fig. 2 and 3) (Silverman and Hulland, 1961). A thin wall of the cyst was found to adhere with the dense fibrous connective tissue over the epicardium. There was displacement of the cardiac tissue beneath the cysts with mild degree of infiltration of mononuclear cells, congestion and haemorrhages.

The microscopic observation of bovine mature cysticercosis recorded in the present study is in agreement with the findings of Silverman and Hulland (1961) and Jones and Hunt (1983). Moreover, sarcocystis in large numbers were seen within the heart muscle which were devoid of any inflammatory reaction. This observation supports the observations of Jones and Hunt (1983), who recorded that the presence of numerous sarcocystis in the heart muscle and in the purkinjee fibre, but without inflammatory reaction.

Since both the cysticercus and sarcocystis have zoonotic importance (McIntosh and Miller, 1960; Shah, 1995), this communication confirms the prevalence of sarcocystis and measly beef in this part of the country.

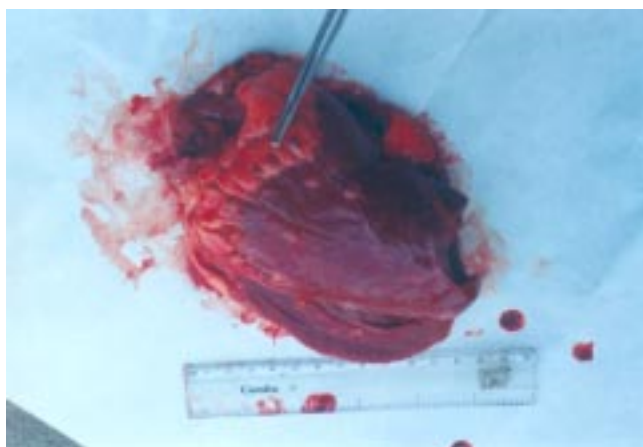


Fig. 1. Photomicrograph of a cyst in heart muscle of a cow.

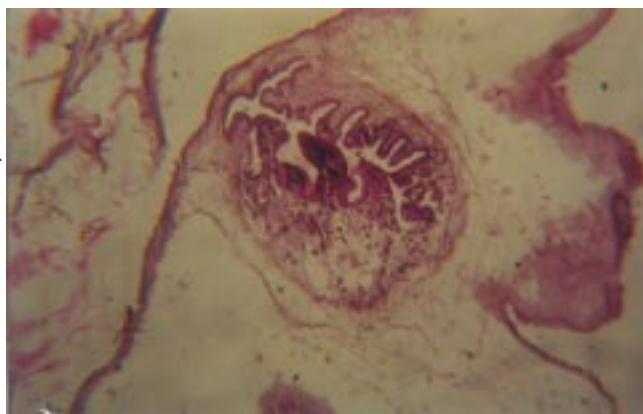


Fig. 2. Photomicrograph showing a *Cysticercus bovis* in heart muscle H & E x100

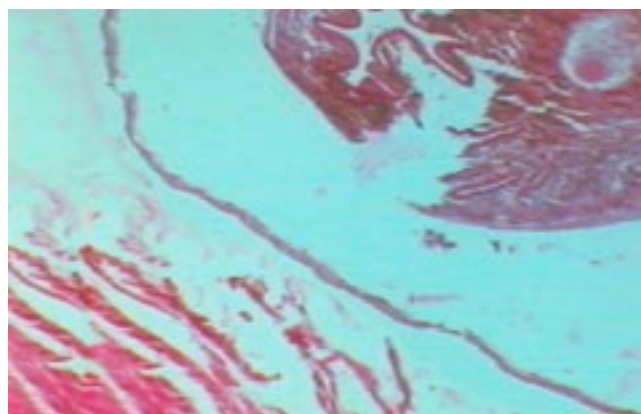


Fig. 3 Another view of *Cysticercus bovis* in the heart muscle, also note the distinct cyst wall

www.IndianJournals.com
Members Copy, Not for Commercial Sale
Downloaded From IP - 44.192.26.226 on dated 11-Sep-2024

References

Githigia, S.M., Kimoro, C.O., Mwangi, D.M. and Gichanga, J., 1995. Prevalence and economic significance of oesophagostomum and other helminth parasites of ruminants : Survey in selected abattoirs around Nairobi, Kenya. Bull. Anim. Hlth. Prod. (Africa), 43: 29-33.

Jones, T.C. and Hunt, R.D., 1983. Diseases caused by parasitic helminths and arthropods. 5th edn. Lea and Febiger, Philadelphia.

McIntosh, A. and Miller, D., 1960. Bovine cysticercosis with special reference to the early developmental stages of *Taenia saginata*. Am. J. Vet. Res., 21: 169-177.

Mori, N., Iketani, O., Abe, N., Hirata, K. and Chinone, S., 1996. An outbreak of bovine cysticercosis in Kanagawa prefecture. J. Japan Vet. Med. Assoc., 49: 467-470.

Ratnam, S. and Khanna, P.N., 1988. Incidence of *Cysticercus bovis* in slaughtered animals and its public health significance. Indian J. Com. Microbiol., Immunol. Infect. Dis., 9: 65-67.

Shah, H.L., 1995. Sarcocystosis as a zoonosis with special reference to India. J. Vet. Parasitol, 9: 57-61.

Silverman, P.H. and Hulland, T.J., 1961. Histological observations on bovine cystocercosis. Res. Vet. Sci., 2: 248-252.

Zivkovic, J., Velimirovic, D., Dzaja, P. and Grabarevic, Z., 1996. Prevalence of *Cysticercus - Bovis S. inermis* measles with particular reference to histopathological changes in meat. Archiv-fur-Lebensmittelhygiene, 47: 66-68.